

# **Treatment of An Infrabony Pocket Adjacent to the Mandibular Right First Molar of an American Eskimo Dog**

Brett Beckman, DVM, FAVD, DAVDC, DAAPM  
Affiliated Veterinary Specialists, Orlando, Florida  
Florida Veterinary Dentistry and Oral Surgery, Punta Gorda, Florida  
Animal Emergency Center of Sandy Springs, Atlanta, GA  
[www.veterinarydentistry.net](http://www.veterinarydentistry.net)  
veterinarydentistry@gmail.com

## **Introduction:**

Graft material has been used successfully to treat vertical osseous (infrabony) defects in humans for many years with a case report presented in the 1950's.<sup>1</sup> Removal of junctional and pocket epithelium followed by the placement of a barrier to discourage the migration of new epithelium into infrabony defects has been shown to allow new attachment of periodontal ligament cells to the root surface and repopulation of bone to the area.<sup>2</sup> A wide variety of substances have been used, with and without the aid of a membrane, to achieve this purpose.<sup>2</sup> This case report describes the use of synthetic bone graft particulate<sup>a</sup> (bioactive glass) and a 24% EDTA gel<sup>b</sup> to treat an infrabony defect adjacent to the mandibular right first molar of an American Eskimo dog.

## **History:**

A seven-year old 13 kilogram, female, spayed American Eskimo dog presented in April 2000 for a routine prophylaxis and oral examination. Dental cleaning had never been performed. No other relevant history existed.

## **Diagnostics:**

Physical examination of the patient was within normal limits. Oral examination was performed with the aid of a nylon muzzle. Limited visualization revealed a gingivitis index of II, a calculus index of II, and a plaque index of II.<sup>3</sup> Further oral evaluation required sedation due to the aggressive nature of the patient.

Pre-anesthetic testing included a complete blood count, serum chemistry profile, urinalysis and EKG. EKG<sup>c</sup> readings showed a normal sinus rhythm, normal complexes and a heart rate of

120. CBC, serum chemistry profile and urinalysis were normal. Mucous membrane color, capillary refill time, pulse and chest auscultation were all within normal limits.

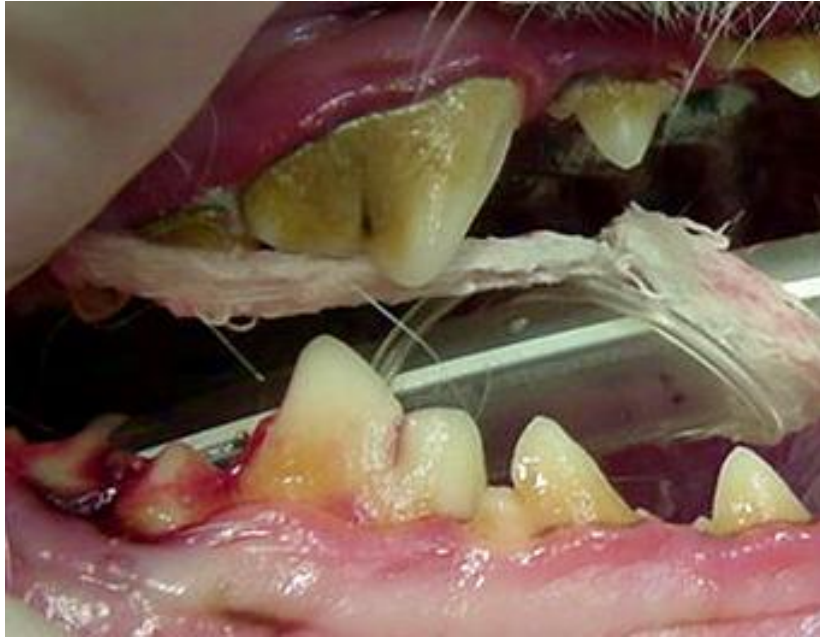
Butorphanol<sup>d</sup> (3.5 mg IM) was given thirty minutes pre-operatively to aid in preemptive and post-operative pain relief.<sup>4</sup> A twenty gauge intravenous catheter<sup>e</sup> was placed in the right cephalic vein. General anesthesia was induced with ketamine<sup>f</sup> (65 mg IV) and valium<sup>g</sup> (2.6 mg IV). The patient was intubated with a 7.0 mm cuffed endotracheal tube<sup>h</sup> and the cuff was inflated gently. The animal was maintained with isoflurane<sup>i</sup> (2.0-2.5%) and oxygen (2.5 L/min) using a semi-closed anesthetic delivery system.<sup>j</sup> The patient was placed on a water-circulated heating pad<sup>k</sup> and was connected to leads for EKG<sup>c</sup> monitoring. A warmed balanced electrolyte solution<sup>l</sup> was administered at 10 ml/kg/hr. Temperature, respiration, pulse and capillary refill time were regularly obtained and recorded by a monitoring technician.

A complete oral examination was performed and abnormalities were noted on the dental chart. In addition to the changes discovered during the initial oral examination the mandibular right second molar (410) had a mobility index of two.<sup>5</sup> A periodontal probe<sup>m</sup> was used to explore the gingiva. A four millimeter periodontal pocket was present on the mesial aspect of tooth 410. The pocket extended to involve the furcation. The furcation was classified as F3 meaning that a periodontal probe<sup>m</sup> could be passed through the furcation with or without soft tissue engagement.<sup>5</sup> A six millimeter pocket was present on the distal aspect of the tooth 409. A slight decrease in furcation bone density was associated with tooth 409 with a slight decrease in alveolar crestal bone density adjacent to the mesial aspect of the tooth. The maxillary right (105) and left (205) first premolars had a mobility index of three.<sup>5</sup> A four millimeter pocket was present around the entire circumference of each tooth. Bleeding was induced with light probing at all affected teeth. (Figure 1) All mandibular incisors had a mobility index of one.<sup>5</sup>

The oral cavity was thoroughly rinsed with 0.12 % chlorhexidine<sup>n</sup> solution. Complete supragingival and subgingival scaling<sup>o</sup> was performed. The teeth were polished using a disposable prophylaxis angle<sup>p</sup> on a slow speed hand-piece<sup>q</sup> and polishing paste<sup>r</sup>. The oral cavity was again rinsed thoroughly with water using an air-water syringe on a high speed delivery system.<sup>q</sup>

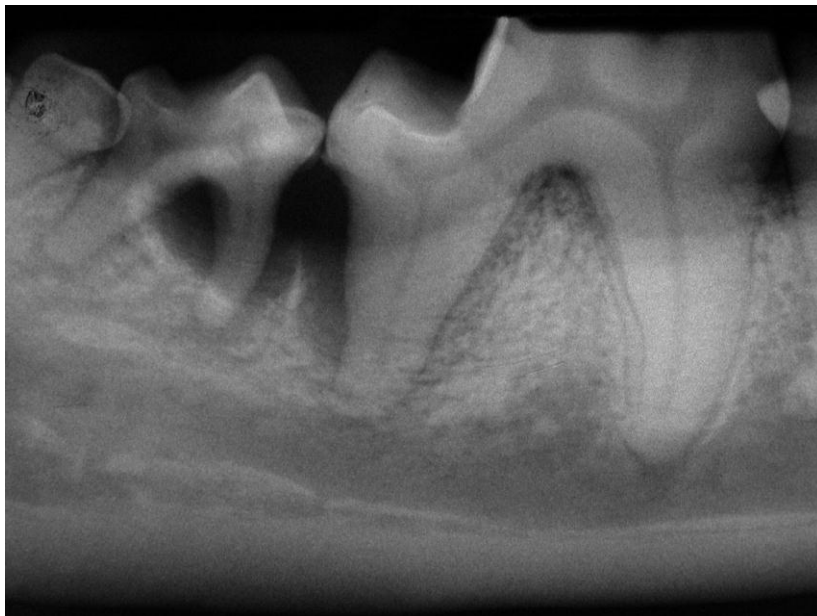
Dental radiographs<sup>s</sup> were to aid in determining the extent of periodontal disease. Bone loss involving the furcation of tooth 410 was extensive. (Figure 2) The mesial root had lost ninety percent of supporting bone. A vertical osseous defect was present along the distal aspect of the distal root of tooth 409 and a 5 millimeter decrease in alveolar crestal bone height was present.

Near total bone loss was present around teeth 105 and 205. A ten to thirty percent decrease in alveolar crestal bone height was present surrounding the mandibular incisors.



(Figure 1)

Bleeding is evident upon probing of the interradicular space between the mandibular right first molar (409) and the mandibular right second molar (410).



(Figure 2)

A deep infrabony pocket is present adjacent to the distal aspect of the root of tooth 409. The mesial root and the furcation of tooth 410 has lost significant bone. Horizontal bone loss is also evident.

**Diagnosis:**

The owner was notified by telephone of the above findings. The patient had Stage IV periodontal disease<sup>3</sup> affecting teeth 105, 205 and 410. Tooth 409 had considerable bone loss affecting the distal root but might be salvaged with the aid of periodontal surgery. The importance of daily tooth brushing and application of chlorhexidine gel<sup>l</sup> to the tooth surface was discussed. Visits for dental prophylaxis and periodontal disease evaluation would need to be scheduled every three to six months for the life of the pet. The owner was willing to comply with these recommendations.

**Treatment Plan:**

The treatment plan included complete supragingival and subgingival scaling,<sup>o</sup> extraction of teeth 105, 205 and 410 and debridement of the alveolus of each extracted tooth. Open debridement and curettage of the region surrounding the distal aspect of tooth 409 would be performed followed by root treatment with 24% EDTA<sup>b</sup>. Bioglass<sup>a</sup> would then be placed. A bioactive glass<sup>a</sup> would also be placed in the extraction site of tooth 410 to augment the alveolar crest adjacent to the defect.

**Treatment:**

The patient was placed in dorsal recumbency. Right and left infraorbital nerve blocks were performed by injecting bupivacaine<sup>u</sup> (2.5 mg) using a tuberculin syringe and a 25 gauge 1 inch needle<sup>v</sup> at the entrance to the right and left infraorbital canals and holding digital pressure over each area for sixty seconds. Aspiration to confirm that the needle was not placed intravascularly was performed prior to each injection. A right inferior alveolar nerve block was performed by advancing the needle to the mandibular foramen using the extraoral technique (6) and by injecting bupivacaine<sup>t</sup> (2.5 mg) following aspiration to confirm the needle was not intravascular. Ampicillin<sup>w</sup> (260 mg) was administered intravenously preoperatively due to stage IV periodontal disease.<sup>7</sup>

The oral cavity was thoroughly rinsed with 0.12 % chlorhexidine<sup>n</sup> solution. Complete supragingival and subgingival scaling<sup>o</sup> was performed. The teeth were polished using a disposable prophylaxis angle<sup>p</sup> on a slow speed hand-piece<sup>d</sup> and polishing paste<sup>f</sup>. The oral cavity was again rinsed thoroughly with 0.12 % chlorhexidine<sup>n</sup> solution.

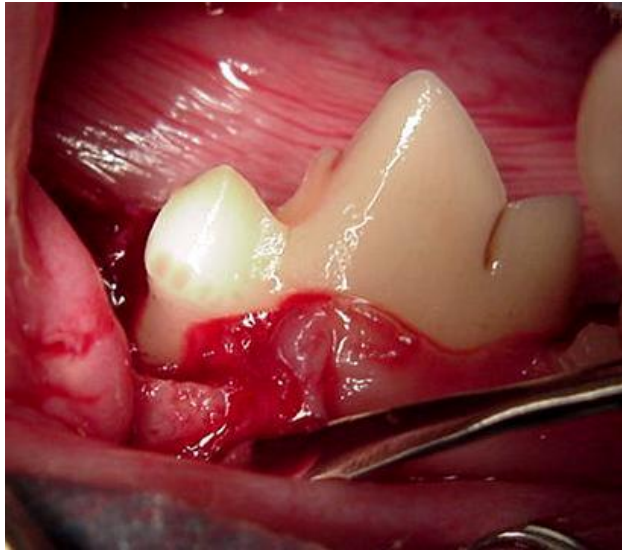
The patient was placed in right lateral recumbency. A 15 Bard Parker blade<sup>x</sup> mounted on a No. 7 scalpel handle<sup>y</sup> was used to incise the epithelial attachment surrounding tooth 205. An EX-W2 winged elevator<sup>z</sup> was used to release any remaining periodontal ligament attachment and the tooth was lifted easily from its socket. An EX-9<sup>aa</sup> periosteal elevator was used to gently debride the alveolus to remove granulation tissue and debris. The alveolus was then copiously flushed with sterile saline solution<sup>bb</sup>. A radiograph was taken using a bisecting angle technique to document complete extraction. The gingiva was sutured in a simple interrupted pattern using Mayo Hagar needle holders<sup>cc</sup> and 4-0 Monocryl® with a P-3 cutting needle.<sup>dd</sup>

The patient was placed in left lateral recumbency and tooth 105 was extracted using an identical technique as that used with tooth 205. No radiographs were taken to document extraction due to the ease of extraction and visual inspection of a complete apex on each tooth.

Tooth 410 was extracted by incising the gingival attachment as described previously. An EX-W3 winged elevator<sup>ee</sup> was used to break any remaining periodontal ligament attachment on both roots. The tooth was easily lifted from its alveolus using the elevator. Debridement and lavage of the alveolus was as previously described.

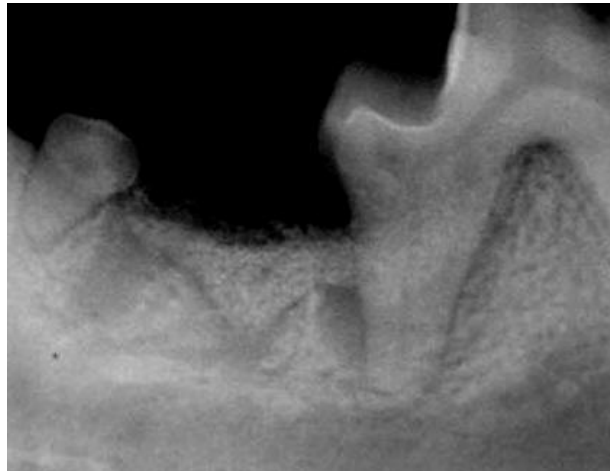
The approach to the infrabony pocket associated with tooth 409 was begun by making an incision in the dorsal gingiva starting at the mesial border of the extraction site and extending to the distal border of tooth 409. A full thickness mucoperiosteal envelop flap was begun, extending the incision in a reverse bevel orientation<sup>8</sup> along the lingual and buccal sulcus of tooth 409 to the level of the furcation. An EX-7 periosteal elevator<sup>ff</sup> was used to extend the envelope flap twelve to fifteen millimeters in an apical direction from the extraction site to the furcation of tooth 409 to expose the infrabony defect. Pocket debridement and root planning was performed with a Gracey curette<sup>gg</sup> and a piezoelectric ultrasonic scaler<sup>o</sup> until no granulation tissue, necrotic cementum or calculus was present on bone or the root surface. (Figure 3) Hemorrhage was controlled with suction.<sup>hh</sup> Gingival curettage was performed using a universal curette<sup>ii</sup> to remove diseased pocket epithelium. Visualization of the defect confirmed a two walled infrabony defect.<sup>5 9</sup> Although radiography can give a preliminary indication the only way to accurately determine the configuration of vertical bone defects is through surgical exposure.<sup>9</sup> 24% EDTA<sup>a</sup> was then applied to the exposed root surface for two minutes. The site was then rinsed with 0.9% sterile saline<sup>bb</sup>. A bioactive glass<sup>a</sup> was mixed with 0.9% sterile saline<sup>bb</sup> and placed to evenly fill the defect and the extraction site of tooth 410. The gingiva was repositioned

and sutured in a simple interrupted pattern using Mayo Hagar needle holders<sup>cc</sup> and 4-0 Monocryl® with a C2 cutting needle.<sup>dd</sup> A radiograph was taken to document placement of Bioglass<sup>b</sup>. (Figure 4) A slight void in the fill was present although it should prove to be clinically insignificant. A blood clot is the most likely reason for this void. Ketoprofen<sup>jj</sup> (9 mg SQ) was administered to aid in postoperative pain control. <sup>10 11</sup> Ketoprofen<sup>jj</sup> is approved for use in Europe and Canada <sup>10</sup> and has proven to be effective for postoperative pain relief. <sup>10 12</sup>



(Figure 3)

An envelope flap is extended from the extraction site of tooth 410 to expose the distal aspect of the distal root of tooth 409. The area is shown here prior to bioactive glass placement.



(Figure 4)

A radiograph was taken after bioactive glass placement to ensure adequate filling of the defect and to document total extraction of tooth 410.

### **Post-Operative Care:**

The patient was placed on a blanket in recovery and carefully monitored. At the first sign of swallowing the endotracheal tube<sup>h</sup> was deflated and removed. The patient was monitored until sternal recumbency was achieved. Prior to discharge, the IV catheter<sup>e</sup> was removed and a light pressure bandage placed over the catheter site to aid in hemostasis. Amoxicillin-Clavulanate<sup>kk</sup> was dispensed with instructions to give one tablet (125mg) and 0.9 ml liquid (62.5 mg/ml) every 12 hours for 7 days. Carprofen<sup>ll</sup> (25mg) was dispensed with instructions to give one tablet daily for 3 days. The owners were instructed to discontinue administration if vomiting occurred. Chlorhexidine gel<sup>l</sup> was dispensed with instructions to apply to the surgical site at teeth 409 and 410 twice daily for two weeks. Soft food was prescribed for two weeks. The owner was instructed to eliminate patient access to chew toys or bones during this period.

### **Long Term Follow Up:**

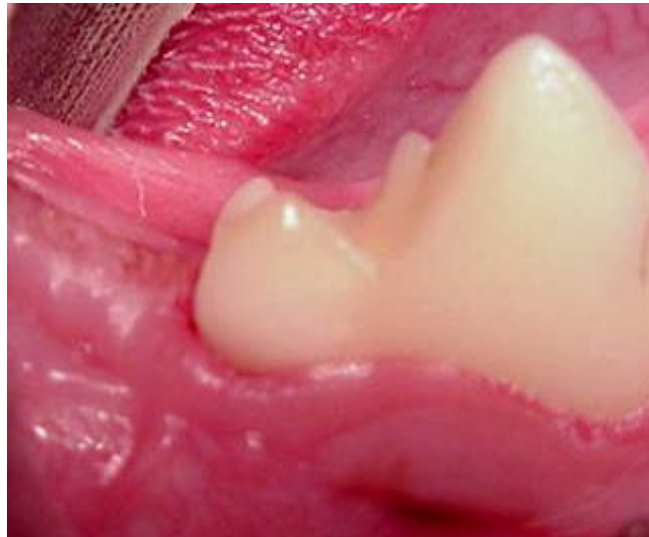An appointment was made for two weeks post-op to examine the surgical site. The day following discharge the owner was contacted by phone to check on the patient. The patient had eaten the evening of the surgery and no problems were detected.

The patient returned for a two-week follow up examination. The patient was examined with the aid of a loose fitting nylon muzzle. There was complete healing of the surgical site and the extraction sites. Toothpaste<sup>mmm</sup> was dispensed and the client was instructed to brush the outside surfaces of all teeth in the am coupled with chlorhexidine<sup>h</sup> gel application every pm for the life of the patient. An appointment was made for three months later for radiographic evaluation of the surgical site at tooth 409, for possible prophylaxis and to check owner compliance with at-home care.

The patient returned eight months post-op. Anesthesia was approached as with the original presentation excluding the CBC, chemistry profile and urinalysis. No gingival inflammation existed. (Figure 5) Complete supragingival and subgingival scaling<sup>o</sup> was performed. A gingivitis index of I and a calculus index of I and plaque index of I was present.<sup>3</sup> Radiography showed excellent bone deposition at the distal aspect of tooth 409. (Figure 6) A one-half millimeter infrabony defect was present. A three millimeter periodontal pocket was present at the distal aspect of tooth 409. It was determined that the owner was compliant with at-home care.

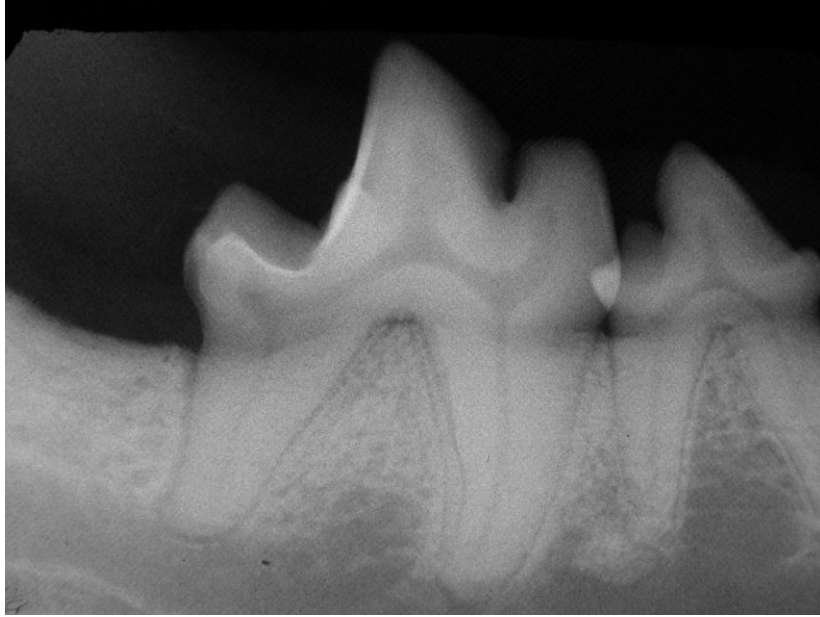It was recommended that the patient return for prophylaxis and evaluation of periodontal disease status every 6 months. The patient returned consistently and the results of the oral examination at each visit were similar to that observed at the original eight month evaluation. A digital picture (Figure 7) and a radiograph (Figure 8) were taken at two years and nine months postoperatively. No additional changes were detected at that time with the exception of Class 6 Stage 2 fractures<sup>13</sup> of the mesial and central cusp on tooth 409. The owner was unaware of the source of the fracture. The animal had no known access to hard substances. A white stone bur<sup>mm</sup> was used to eliminate unsupported enamel rods and smooth the defect. The area was then etched<sup>nn</sup> for 40 seconds, rinsed and dried with an oil free air source.<sup>o</sup> Then a thin layer of primer<sup>oo</sup> was placed in the access site, left for 30 seconds, rinsed and dried. A thin layer of unfilled resin<sup>pp</sup> was then placed, lightly blown with an oil free air source to thin, and then light cured<sup>qq</sup> for 40 seconds to seal exposed dentinal tubules according to manufacturers recommendations. The process from etching forward was repeated and the defects were polished using a composite polishing paste<sup>rr</sup>.

The owner was instructed to continue at-home care and return every 6 months for cleaning and evaluation. A CBC, chemistry profile, and urinalysis would be performed yearly prior to anesthesia. Thorough evaluation prior to anesthesia would be done every six months as described with the original anesthetic episode.



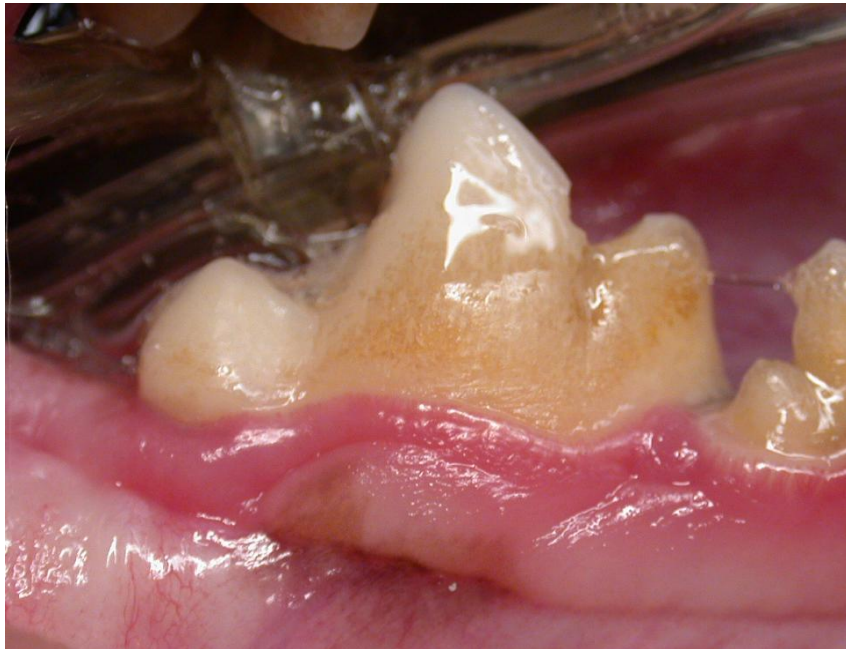(Figure 5)

The surgical site at eight months post-operatively shows normal gingiva. Probing depths were two to three millimeters around the distal aspect of tooth 409.



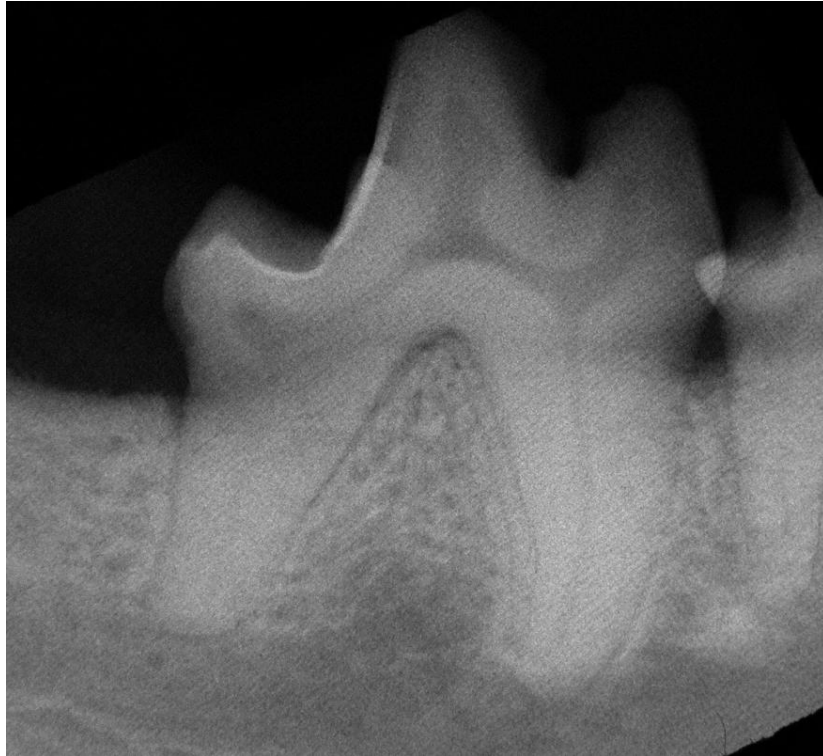(Figure 6)

Radiographs show a one-half millimeter infrabony pocket at the distal aspect of the distal root.



(Figure 7)

Tooth 409 exhibits plaque, gingivitis and a tartar indices of I at two years and nine months post-operatively. Class 6 Stage 2 fractures of the mesial and central cusp are present.



(Figure 8)

At two years and nine months post-operatively no increase in the infrabony pocket depth of tooth 409 is seen radiographically

### **Discussion:**

The goal and rationale in approaching surgical therapy for infrabony pockets is to create the ideal environment for new attachment of periodontal ligament fibers to new cementum and for gingival epithelium to adhere to tooth structure.<sup>14</sup> This process starts with the provision of adequate visualization with the aid of a mucoperiosteal flap. This allows the operator to thoroughly clean diseased tissue from the defect and the gingiva through root planning and subgingival curettage. Once completed, a variety of products may be used to enhance the healing effort to create new attachment.

Several compounds are currently in use to biomodify the root surface to enhance new attachment. Discussion of all such compounds is beyond the scope of this paper, however citric acid and 24% EDTA are two common compounds traditionally used for root surface treatments. Both act to demineralize the root surface in an attempt to expose collagen fibers creating an ideal surface for population with periodontal ligament cells.<sup>15 16</sup> It has been shown that treatment

with both agents attract fibroblasts<sup>16</sup> that act with other cells to initiate the process of collagen synthesis which is the structural component of periodontal ligament fibers.<sup>17</sup> 24% EDTA was chosen in this case for several reasons. Although effective at demineralizing the root surface citric acid has a necrotizing effect on the surrounding tissues due to its low ph.<sup>18</sup> 24% EDTA operates at a neutral ph and promotes the healing of periodontal tissue.<sup>19</sup> Materials used for grafting in infrabony defects are also classified regarding their ability to be osteogenic, osteoinductive or osteoconductive.<sup>2,20</sup> Osteogenic compounds have cells capable of synthesizing new bone within the compound itself. The most common example of an osteogenic graft material is cancellous bone grafts from the patient.<sup>2</sup> The added anesthesia time and technical difficulty involved with obtaining this material makes it a less viable choice despite the desirability of its osteogenic nature. Osteoinductive materials contain cells that promote patient cell transformation to osteoblasts.<sup>2,20</sup> One such material is decalcified freeze-dried bone allograft (DFDBA) which contains bone morphogenic protein.<sup>2</sup> Although an excellent alternative to autogenous bone grafts cost is a major deterrent with this material. Osteoconductive compounds act as a matrix for migration of cells that aid in the production of new bone.<sup>2,20</sup> Examples include hydroxyapatite, tricalcium phosphate and bioactive glass. Bioactive glass was the compound used in this case for several reasons. It is approved for veterinary use as a grafting material to treat infrabony defects.<sup>21</sup> It has been shown to be effective in treating infrabony defects in humans<sup>2,22,23</sup> and in the dog and cat<sup>21</sup>.

It is capable of impeding the downgrowth of epithelial tissues that prevent new attachment of the periodontal ligament<sup>21,24</sup> and has proven superior to hydroxyapatite and tricalcium phosphate in its ability to do so.<sup>21</sup> It has also been shown to have an antibacterial effect against oral microbes in vitro.<sup>25,26</sup>

Consideration was given to the use of a membrane to aid exclusion of unwanted tissue migration into the pocket during healing. Research involving Class II furcations in humans has shown no benefit when using a membrane over that of bioactive glass.<sup>27</sup> The favorable long term outcome described in this case report supports the use of bioactive glass<sup>b</sup> and 24% EDTA<sup>a</sup> in the manner described to treat infrabony defects in dogs.

**Products:**

- a) Prefgel, Biora Inc., Chicago, IL
- b) Consil, Nutramax Laboratories, Baltimore, MD
- c) EKG analyzer, Vetronics, Lafayette, IN
- d) Torbugesic, Fort Dodge Animal Health, Fort Dodge, IA
- e) Surflo intravenous catheter, Terumo Medical Corp, Elkton, MD
- f) Ketaset, Fort Dodge Animal Health, Fort Dodge, IA
- g) Valium, Abbott Laboratories, N Chicago, IL
- h) 5-0 Endotracheal Tube, Rusch, Deluth, GA
- i) IsoFlo, Abbott Laboratories, N Chicago, IL
- j) VMS Anesthesia Machine, Matrix Medical, Inc., Orchard Park, NY
- k) T Pump, Gaymar Industries, Orchard Park, NY
- l) Lactated Ringer's solution, Abbott Labs, N Chicago, IL
- m) P2 Probe/Explorer Combination, Cislak Manufacturing Inc., Glenview, IL
- n) Chlorhexidine, First Priority, Elgin, IL
- o) Neosonic, Amdent, Cherry Hill, NJ
- p) Disposable prophylaxis angle, Carlile Labs, Rockwell Centre, NY
- q) High Speed Delivery System, Beaverstate Dental, Tualatin, OR
- r) Prophyl 1 Paste, Carlile Labs, Rockville Centre, NY
- s) DentX Image Vet X70, AFP Imaging, Elmsford, NY
- t) CET gel, Virbac, Fort Worth, TX
- u) Bupivacaine 0.5 %, Abbott Laboratories, N Chicago, IL
- v) Tuberculin syringe and needle, Nipro Medical Corp, Miami, FL
- w) Ampicillin sodium, Geneva Pharmaceuticals, Dayton, NJ
- x) No. 15 surgical blade, Carlile Labs, Rockville Centre, NY
- y) Scalpel handle, Spectrum, Stow, OH
- z) EX-W2 winged elevator, Cislak Manufacturing Inc., Glenview, IL
- aa) EX -9 periosteal elevator, Cislak Manufacturing Inc., Glenview, IL
- bb) 0.9% saline solution, Abbott Labs, N Chicago, IL
- cc) Mayo-Hagar needle holders, Spectrum, Stow, OH
- dd) 5-0 Monocryl®, Ethicon, Inc. Somerville, NJ

- ee) EX-W3 winged elevator, Cislak Manufacturing Inc., Glenview, IL
- ff) EX-7 periosteal elevator, Cislak Manufacturing Inc., Glenview, IL
- gg) P22 Double ended Gracey curette, Cislak Manufacturing Inc., Glenview, IL
- hh) Suction Unit, Shuco, Toledo, OH
- ii) Universal curette, Henry Schein, Melville, NY
- jj) Ketofen, Fort Dodge Animal Health, Fort Dodge, IA
- kk) Clavamox, Pfizer Animal Health, NY, NY
- ll) Rimadyl, Pfizer Animal Health, NY, NY
- mm) White stone bur, Carlile Labs, Rockville Centre, NY
- nn) Scotchbond etchant, 3M Company, St. Paul, MN
- oo) Scotchbond multipurpose primer, 3M Company, St. Paul, MN
- pp) Scotchbond multipurpose adhesive, 3M Company, St. Paul, MN
- qq) Light Cure, Carlile Labs, Rockwell Centre, NY
- rr) High Gloss Polishing Paste, Henry Schein, Melville, NY

### **References:**

1. Carranza, FA Sr: A technic for reattachment. J Periodontol 25:272 (1954)
2. Carranza FA et al Regenerative Osseous Surgery In: Clinical Periodontology, 9<sup>th</sup> Edition Saunders, Philadelphia, WB Saunders 809-820 (2002)
3. Wiggs RB, Lobprise HB. Periodontology. In: Wiggs RB, Lobprise HB Veterinary Dentistry Principles and Practice. Philadelphia, Lippincott, 196-199 (1997)
4. Brearley JC, Brearley MJ Chronic Pain in Animals In: Pain Management in Animals, London, WB Saunders 153-154 (2000)
5. Wiggs RB, Lobprise HB. Periodontology. In: Wiggs RB, Lobprise HB Veterinary Dentistry Principles and Practice. Philadelphia, Lippincott, 202-206 (1997)
6. Beckman BW, Legendre L Regional Nerve Blocks for Oral Surgery in Companion Animals Comp Cont Ed Prac Vet 2002 June; 24 (6):439-44.
7. Wiggs RB, Lobprise HB. Periodontology. In: Wiggs RB, Lobprise HB Veterinary Dentistry Principles and Practice. Philadelphia, Lippincott, 212-213 (1997)
8. Homstrom SE, Frost P, Eisner ER Veterinary Dental Techniques for the Small Animal Practitioner, 2<sup>nd</sup> edition, Philadelphia, W.B. Saunders 184 (1998)

9. Carranza FA Bone Loss and Patterns of Destruction In: Clinical Periodontology, 9<sup>th</sup> Edition Saunders, Philadelphia, WB Saunders 363-365 (2002)
10. Plumb, DC Veterinary Drug Handbook, 4<sup>th</sup> ed Ames, IO, Iowa State Press VIN (2002)
11. Dobromylskyj P et al, Postoperative and Acute Pain In: Pain Management in Animals, London, WB Saunders 119 (2000)
12. Dobromylskyj P et al, Postoperative and Acute Pain In: Pain Management in Animals, London, WB Saunders 40 (2000)
13. Wiggs RB, Lobprise HB. Operative and Restorative Dentistry. In: Wiggs RB, Lobprise HB Veterinary Dentistry Principles and Practice. Philadelphia, Lippincott, 352-355 (1997)
14. Carranza FA Rationale for Periodontal Treatment In: Clinical Periodontology, 9<sup>th</sup> Edition Saunders, Philadelphia, WB Saunders 507-511 (2002)
15. Bergenholtz A, Babay N Scanning electron microscopy of the root surface texture of extracted periodontally diseased teeth following various etching and chelating regimens. *Int J Periodontics Restorative Dent* 1998 Apr;18(2):171-9
16. Babay N Attachment of human gingival fibroblasts to periodontally involved root surface following scaling and/or etching procedures: a scanning electron microscopy study. *Braz Dent J* 2001;12(1):17-21
17. Carranza FA Tooth Supporting Structures In: Clinical Periodontology, 9<sup>th</sup> Edition Saunders, Philadelphia, WB Saunders 35-42 (2002)
18. Blomlof JP, Blomlof LB, Lindskog SF Smear removal and collagen exposure after non-surgical root planing followed by etching with an EDTA gel preparation. *J Periodontol* 1996 Sep;67(9):841-5
19. Blomlof J, Jansson L, Blomlof L, Lindskog S Root surface etching at neutral pH promotes periodontal healing. *J Clin Periodontol* 1996 Jan;23(1):50-5
20. Wiggs RB, Lobprise HB. Periodontology. In: Wiggs RB, Lobprise HB Veterinary Dentistry Principles and Practice. Philadelphia, Lippincott, 222 (1997)
21. Deforge DH, Evaluation of Bioglass/Perioglass (Consil) synthetic bone graft particulate in the dog and cat. *J Vet Dent* 1997 Dec;(14):4
22. Han J, Meng H, Xu L Clinical evaluation of bioactive glass in the treatment of periodontal intrabony defects *Zhonghua Kou Qiang Yi Xue Za Zhi* 2002 May;37(3):225-7
23. Park JS, Suh JJ, Choi SH, Moon IS, Cho KS, Kim CK, Chai JK Effects of pretreatment

clinical parameters on bioactive glass implantation in intrabony periodontal defects. *J Periodontol* 2001 Jun;72(6):730-40

24. Karatzas S, Zavras A, Greenspan D, Amar S Histologic observations of periodontal wound healing after treatment with PerioGlas in nonhuman primates. *Int J Periodontics Restorative Dent* 1999 Oct;19(5):489-99
25. Allan I, Newman H, Wilson M Particulate Bioglass reduces the viability of bacterial biofilms formed on its surface in an in vitro model. *Clin Oral Implants Res* 2002 Feb;13(1):53-8
26. Stoor P, Soderling E, Salonen JI Antibacterial effects of a bioactive glass paste on oral microorganisms. *Acta Odontol Scand* 1998 Jun;56(3):161-5
27. Yukna RA, Evans GH, Aichelmann-Reidy MB, Mayer ET Clinical comparison of bioactive glass bone replacement graft material and expanded polytetrafluoroethylene barrier membrane in treating human mandibular molar class II furcations. *J Periodontol* 2001 Feb;72(2):125-33