

STEP-BY-STEP

Split Palatal U-Flap for Repair of Caudal Palatal Defects

Brett W. Beckman, DVM

Caudal palatal defects may occur secondary to congenital abnormalities, and trauma from foreign body impalement, falls, automobile injury, or bites. Defects in this location extend into the nasal cavity often causing a mucopurulent nasal discharge indicative of chronic bacterial sinusitis. A split-U flap technique for repair of caudal palatal defects using a cadaver specimen is described step-by-step.¹

Figure 2

Oral photograph showing repair of a simulated caudal hard palate defect in a cadaver specimen. It is important that the wound margins be located over bone at wound closure. Enlarging the defect to expose several millimeters of bone around the entire circumference of the defect facilitates bony support of the wound closure. The scalpel blade is maintained perpendicular to the hard palate removing all diseased tissue. Any debris is gently flushed from the nasal cavity. Rough bone edges should be removed with a carbide or diamond bur.

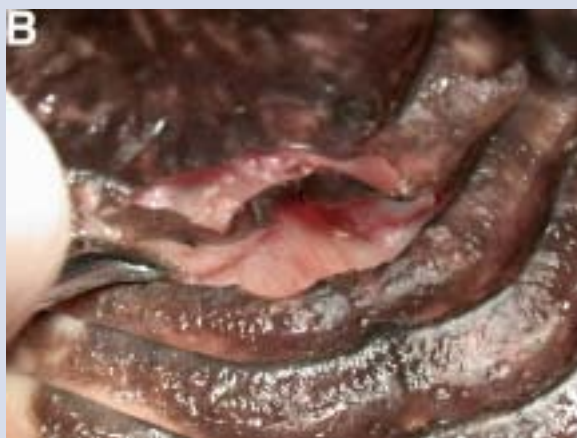
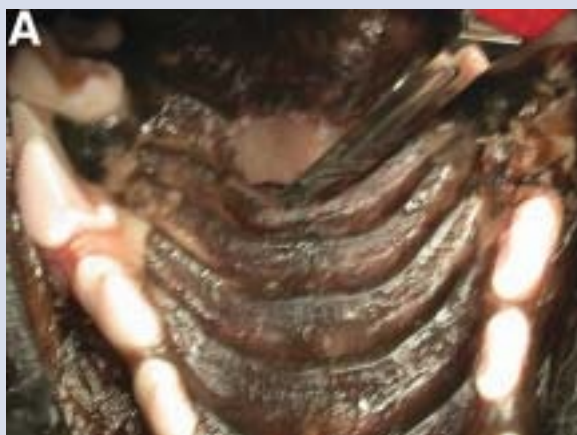
Figure 1

Oral photograph showing a simulated caudal palatal defect in a cadaver specimen. The procedure should begin with a maxillary nerve block performed bilaterally.²

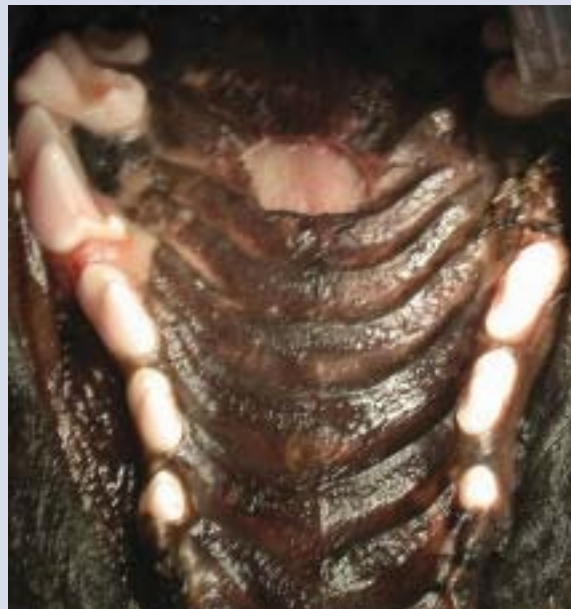

Figure 3

Oral photograph showing repair of a simulated caudal hard palate defect in a cadaver specimen. The palatal mucoperiosteum is incised 3 to 4-mm from the maxillary arcade in each quadrant extending to the level of the first or second premolar. Flap incisions begin at the level of the rostral aspect of the defect. The size of the defect, and the patient breed and species must be considered to determine the rostral extent of these incisions.

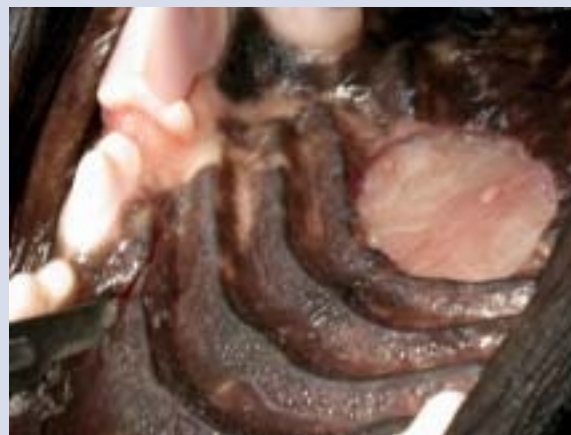

Figure 4

Oral photograph showing repair of a simulated caudal hard palate defect in a cadaver specimen. After the incisions are joined to form a large U-shaped palatal mucoperiosteal flap, a midline incision is made at the rostral aspect of the defect (A) and extended to the rostral portion of the flap to split the U-shaped flap into two portions (B).

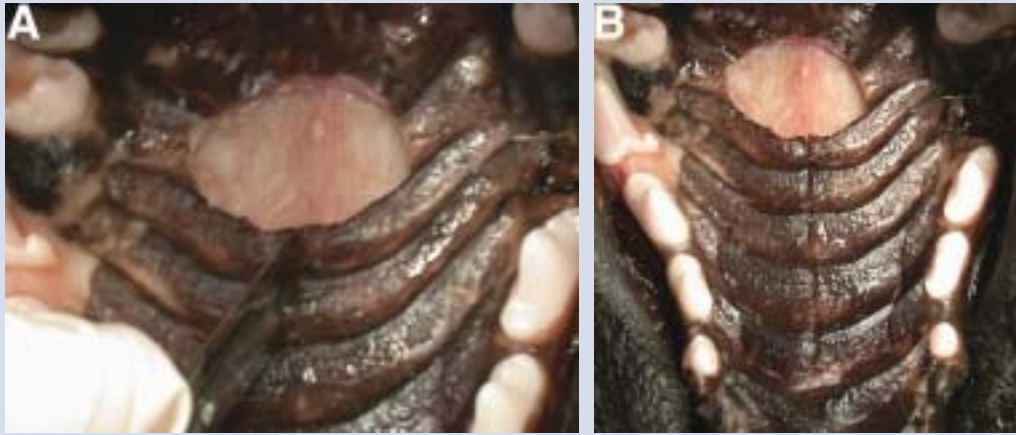

Figure 5

Oral photograph showing repair of a simulated caudal hard palate defect in a cadaver specimen. Care is taken to isolate and ligate the rostral aspect of the greater palatine artery bilaterally at this level (A). A periosteal elevator is used to raise the mucoperiosteal flap at the rostral extent of the defect. Stay sutures are placed to aid atraumatic manipulation of the palatal tissue during further elevation (B).

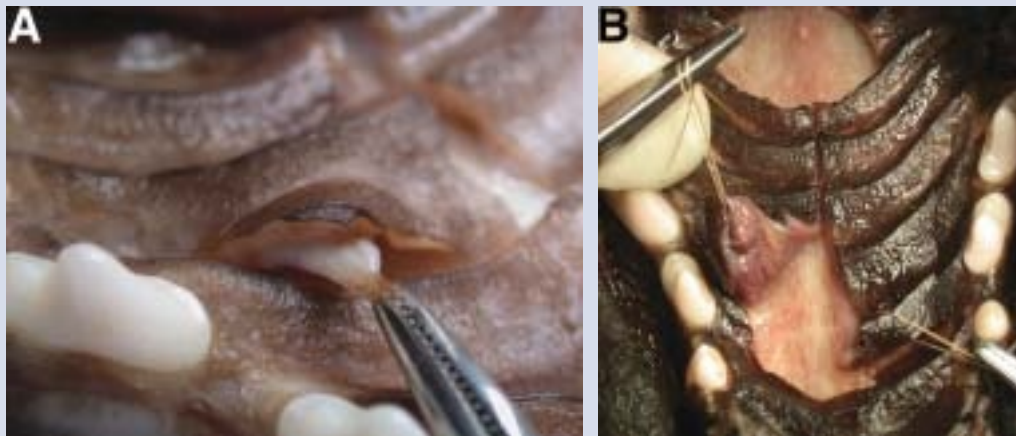


Figure 6

Oral photograph showing repair of a simulated caudal hard palate defect in a cadaver specimen. The flap is carefully elevated caudally to avoid the greater palatine artery as it emerges from the palatine foramen at the level of the maxillary fourth premolar.

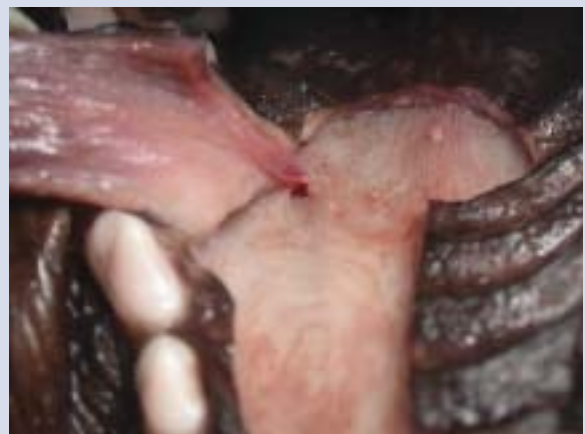

Figure 7

Oral photograph showing repair of a simulated caudal hard palate defect in a cadaver specimen showing position of both portions of the flap before rotation.

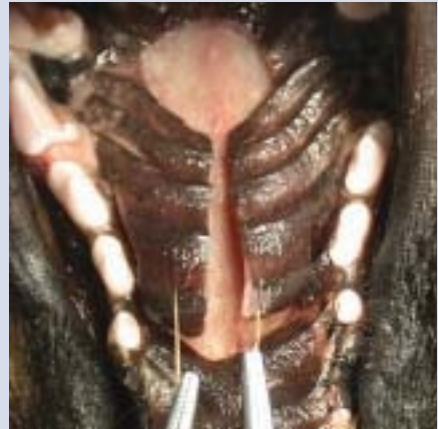
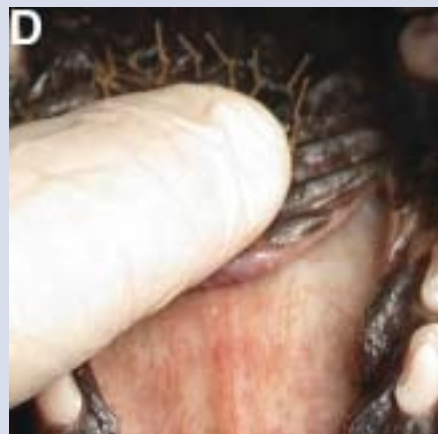
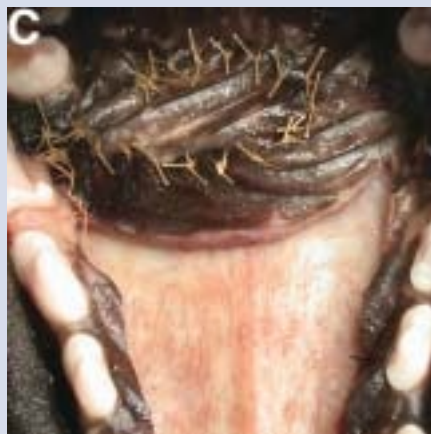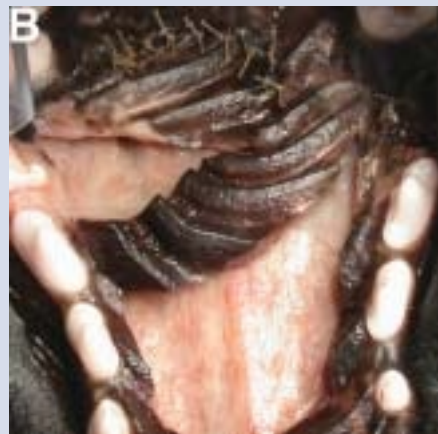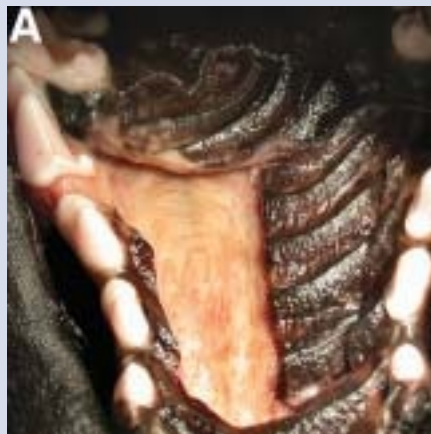Figure 8

Oral photograph showing repair of a simulated caudal hard palate defect in a cadaver specimen. The left side of the flap is rotated into the defect (A). The incision adjacent to the dental arcade may be extended caudally to provide additional mobility of the flap if needed. Also, the flap may need to be trimmed to accommodate the contour of the defect. Absorbable 3-0 or 4-0 sutures (poliglecaprone, polyglactin 910, or chromic gut) are placed in a simple interrupted pattern at 2 to 3-mm intervals to secure the flap to the caudal extent of the defect (B). The right flap is then trimmed as needed and sutured in place adjacent to the left flap using the same suture and pattern (C). Digital pressure is used to displace air bubbles and blood clots under the flap to aid accommodation of the flap to the palatal bone surface (D). The exposed palatal bone will heal by reepithelialization. Preemptive and post-operative pain management utilizing a cox-2 selective NSAID and an opiate should be employed for 3-5 days. Systemic antibiotics should be considered based on the medical status of the case.



Author Information

Brett Beckman, DVM, FAVD
Florida Veterinary Dentistry & Oral Surgery
11002 Nathan Court, Punta Gordo, FL 33955
Email: apetdoctor@aol.com

References

1. Marretta, SM, Grove TK, Grillo, JF. Split palatal U-flap: a new technique for repair of caudal hard palate defects. *J Vet Dent* 1991; 6: 5-8.
2. Beckman BW, Legendre L. Regional nerve blocks for oral surgery in companion animals. *Comp Cont Ed Prac Vet* 2002; 24: 439-44.